Liver abscess in a child: A case report

John Chol Ajack[1,2,3], Joel Taban Mawa[2,3,4], Ring Manut Biar[2]

Author Affiliation:

1. Department of Surgery, Juba Teaching Hospital, Juba, South Sudan
2. St. Kizito Medical Centre, Juba, South Sudan
3. School of Medicine - University of Juba, Juba, South Sudan
4. Al Sabbah Children's Hospital, Juba, South Sudan

Correspondence:
John Chol Ajack
johncholajack@gmail.com

Submitted: April 2026
Accepted: August 2026
Published: November 2026

ABSTRACT

Liver abscess is rare but carries a high risk to life. Risk factors include low immunity and malnutrition. Infection usually reaches the liver through blood, penetrating trauma, and spread from intra-abdominal conditions such as ruptured appendicitis or diverticulitis. An 18-month-old boy presented with fever and abdominal pain for four weeks, progressive abdominal distension for two weeks, and anorexia and vomiting for ten days. On examination, he looked very sick with marked loss of weight, pale but not jaundiced. He was febrile and tachycardic, with abdominal distension and tenderness in the right upper quadrant, and a palpable liver edge at five centimetres below the costal margin. A CT abdominal scan was done and showed a large liver abscess. Laparotomy was done through a Kocher incision, and the abscess was drained. The pus showed no growth on culture. Ultrasonography is considered the main diagnostic tool for liver abscess. However, ultrasound gave a misleading initial diagnosis, which may reflect the need for more training and experience. Radiological assessment plays an important role in the diagnosis. Therefore, improvement in radiological interpretation and experience would aid the diagnostic process.

Keywords: liver abscess, child liver abscess, radiological assessment, St. Kizito Medical Centre, South Sudan

Introduction

A liver abscess is rare but carries a high risk to life. Risk factors include low immunity status, malnutrition, and comorbidities such as diabetes mellitus. Four main groups of organisms can cause liver abscess: bacteria, fungi, protozoa, and parasites.[1] Although falling, the mortality rate remains between 10% and 20%.[2]

Infection usually reaches the liver by haematogenous spread, inoculation through penetrating trauma, or blunt trauma, and spread from an intra-abdominal condition such as ruptured appendicitis or diverticulitis. However, about half of cases nowadays are due to biliary system infections.[2] In children, liver abscess occurs more often in males than females, but there is no clear explanation for this difference. It occurs more commonly in the right lobe of the liver.[3]

Children with liver abscess usually present with nonspecific symptoms of fever, chills, and abdominal pain. On physical examination, there is usually right hypochondrial tenderness, and the liver may be enlarged.[4] The diagnosis is made by clinical evaluation and radiological imaging. Prognosis depends on the

Citation: Ajack et al. Liver abscess in a child: A case report.. South Sudan Medical Journal, 2026;19(4):267-271
© 2026 The Author (s) License: This is an open access article under CC BY-NC
DOI: https://dx.doi.org/10.4314/ssmj.v19i4.10

time from diagnosis to onset and the quality of care and management.[5]

Treatment options vary according to the size of the abscess and include conservative management with a long course of antibiotics alone, percutaneous drainage, ultrasound-guided aspiration, and open surgery.[6]

Case report

The patient was seen and managed at Saint Kizito Medical Centre in Juba, South Sudan. An 18-month-old boy presented with fever and abdominal pain for four weeks, progressive abdominal distension for two weeks, anorexia and vomiting for ten days.

Initially, the child was taken to a clinic with fever, abdominal pain, and loose stool and was diagnosed with malaria and gastroenteritis. Oral antimalarials and antibiotics were given for five days, but without improvement, and the intermittent fever continued. A week later, the child was taken to a surgeon who requested an abdominal ultrasound scan and complete blood count (CBC) (Table 1). A hepatoblastoma was diagnosed.

They were told that the child had a malignant liver and would need a liver transplant outside the country. Resources for this were unavailable. Intravenous antibiotics (a third-generation cephalosporin and metronidazole) were given.

The family took the child to a paediatrician for another opinion. A CBC, malaria test, CT abdominal scan and alpha-fetoprotein were requested. CBC showed severe anaemia (7.1g/dl) and a very high WBC count (Table. 1). The CT scan showed a large liver abscess (about 300 ml) at segment VII (i.e. the extreme upper right) (Figure 1). The alpha-fetoprotein was negative. Stool analysis was mucoid with numerous pus cells. Hepatitis B and C virus tests and an HIV test were negative.

On examination the child was very sick with marked loss of weight, pale but not jaundiced. He was febrile with temperature of 39°C, and tachycardia (a pulse rate of 140 beats per minute), abdominal distension, a tender right upper quadrant, and palpable liver edge at 5 centimetres below the costal margin.

Table 1. Patient Complete Blood Count (CBC) profile

Parameter	10 days pre-operative	4 days pre-operative	4 days post-operative	4 weeks post-operative	Normal range	Units of measurement
WBC	16.7	32.4	12.4	9.5	4.0 – 10.0	10^9/L
Lymphocytes	5.1	5.7	5.100	5.2	0.8 – 4.0	10^9/L
Mixed Cells	1.7		1.0	0.7	0.1 – 1.5	10^9/L
Granulocytes	9.9		6.3	3.6	2.0 – 7.0	10^9/L
Lymphocytes	30.5		41.2	54.5	20 – 40	%
Mid-sized white blood cell count.	10.3		8.3	7.4	3 – 15	%
Granulocytes	59.2	26.5	50.5	38.1	50 -70	%
Red blood cell count	3.11	5.0	5-00	4.55	4.00 – 5-50	10^12/L
Haemoglobin	7.1	10.6	12-7	12.5	13.0 – 18.0	g/dl
Haematocrit	21.4	35.2	35.5	33.1	40-0 – 54.0	%
MCV	68.1	72.4	70.9	72.7	80.0 – 100	fL
MCH	26.2	22.1	25.4	27.5	27.0 – 34.0	pg
MCHC	34.2	30.2	35.8	37.8	32.0 – 36.0	g/dl
RDW-CV	0.227		0.226	21.9	11.0 – 16.0	%
RDW-SD*	56.7		56.2	55.9	35-0 – 56.0	fL
Platelets	517	535	125	274	150 – 450	10^9/L
MPV	8.6		8.9	7.9	6.5 – 12.0	fL
PDW	15.5		15.9	16.0	15.0 – 17.0	Absolute
Plateletcrit	0.445		0.111	0.218	0.108 – 0.282	%

*Red Cells Distribution Width – Standard Deviation

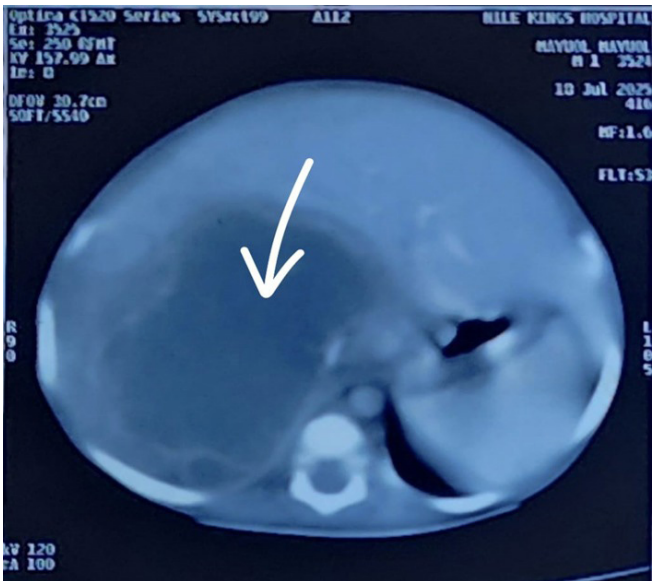

Figure 1. CT abdomen showing large hepatic abscess at segment VII (Photo credit - John Chol)

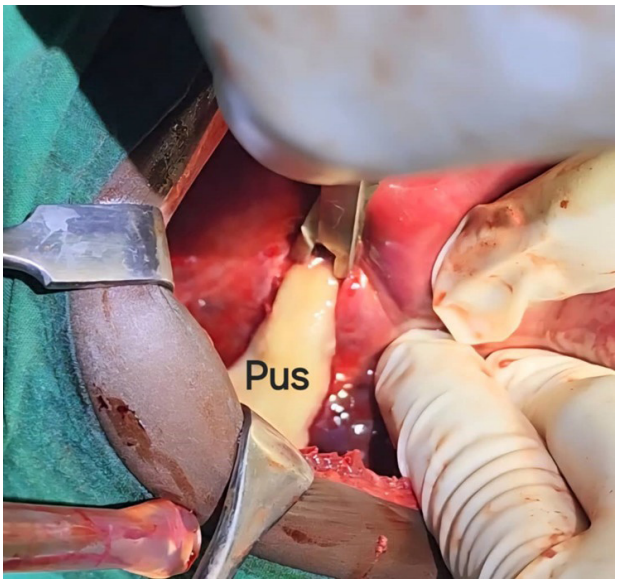

Figure 2. Intraoperative picture showing thick pus from the liver. (Photo credit - John Chol)

Liver function tests showed an increased serum alkaline phosphatase (ALP) (118.2 IU/l, normal value 26 – 117 IU/l); renal function tests were normal, but electrolytes showed low serum potassium (2.3 mmol/l, normal 3.5 -5.5 mmol/l) and low serum chloride (87.9 mmol/l, normal 95 – 115 mmol/l.

A decision was made to drain the abscess based on its size and unsatisfactory response to antibiotics over five weeks. The child received two units of blood transfusion before the laparotomy. Laparotomy was done through a Kocher incision, and a large abscess was drained of approximately 300 mL of thick yellowish pus (Figure 2). Intravenous antibiotics continued, and because of blood loss during surgery, the child was transfused with another two units of blood on postoperative days two and three.

During the first postoperative day, the child remained febrile with mild vomiting and developed a cough on day four postoperatively. The CBC on day four showed a reduction in the leucocyte count (Table. 1).

The child dramatically improved. His appetite returned, as did his social interactions. The abdominal pain and swelling subsided gradually within the first week post-surgery. He was discharged from the hospital on the 19th postoperative day with satisfactory wound healing.

Follow-up four weeks later showed the child to be well with a healthy surgical scar and no abnormal signs. CBC was normal (Table. 1). The prognosis was considered very good at this time. Long-term follow-up was done at 6-month and 12-month intervals; the child was very well with normal developmental milestones.

Discussion

The incidence of liver abscess worldwide is very rare, including in South Sudan, which contributes to limited experience in diagnosis and management. It often presents with nonspecific symptoms, making clinical diagnosis difficult. Reaching a clear diagnosis is therefore based on radiological imaging.[7] Due to its availability, affordability, and non-invasiveness, ultrasonography is considered the main diagnostic tool.[8] However, in our case, ultrasound gave a misleading diagnosis, suggesting the need for more training and experience.

There are many risk factors for liver abscess, and their identification plays an important role in clinical judgment. Our case was diagnosed initially with gastroenteritis, and this may have predisposed to infection with gastrointestinal pathogens via the haematogenous route.[4]

Studies showed that poor hygiene and prolonged exposure of a child to a pathogen were etiological factors among different paediatric age groups.[9] Also, in light of the clinical picture, the duration of the symptoms, and the high WBC count, a diagnosis of sepsis should be considered as a predisposing factor for developing liver abscess in this child.[9,10] Immunological workup (e.g., testing of the

complement system and CD4 and CD8 lymphocytes) was not possible because of limited resources. With poor radiological facilities and expertise, a careful clinically based decision is crucial.

Studies suggest treating a small liver abscess with antibiotics alone.[10] In our case, the decision for surgical drainage was made given the inadequate response to a prolonged course of antibiotics and the large size of the abscess. Studies suggest that large abscesses benefit more from surgical drainage.[2,11]

Antibiotic therapy is essential in the management of liver abscess. Our child was treated with intravenous third-generation cephalosporin and metronidazole in the pre-operative and perioperative periods and continued post-operatively for two weeks, as supported by other studies.[9,12, 13]

Postoperative complications are often very common in a patient with liver abscess.[11] Our child developed fever on the first postoperative day, with vomiting and a mild cough on the fourth postoperative day. Paracetamol IV was initiated for fever, and promethazine syrup was given for vomiting, along with a cough syrup.

Anaemia is common in liver abscess,[14] and our child was transfused in both preoperative and postoperative periods.

Bacterial culture of the pus was negative, as with most liver abscesses,[15] probably because of prior antibiotic use.[10]

Conclusion

Liver abscess in paediatrics is rare but should be considered in a child who presents with nonspecific symptoms and abdominal distension even in the absence of risk factors.

Radiological assessment plays an important role in diagnosis; therefore, improved radiological interpretation and experience would aid the diagnostic process.

Open surgery (incision and drainage) of liver abscess is essential, especially in a large abscess.

Funding: None

Limitations: A single case: a series would be more informative.

Conflicts of interest: None.

References

1. Kozielewicz DM, Sikorska K, Stalke P. Liver abscesses – from diagnosis to treatment. Clin Exp Hepatol. 2021 Dec;7(4):329–36. https://doi.org/10.5114/ceh.2021.110998.
2. Wadhera S, Arora N, Dhibar DP. Review: Modern Management of Liver Abscess. J Gastrointest Infect 2022; 12:86–93. https://doi.org/10.1055/s-0043-1760740.
3. Viswanathan MS, Arun Raghavendra BE. Management of Liver Abscess in a Child. PGLJ 2019; 1(3); 8-12. https://doi.org/10.5005/jp-journals-11009-0021.
4. Grossar L, Hoffman I, Sokal E, Stéphenne X, Witters P. Liver abscesses in the Western pediatric population. Acta Gastroenterol Belg. 2022 Jul-Sep;85(3):439-445. https://doi:10.51821/85.3.10211.
5. Kanté M et al. Child Liver Abcess: Study of 12 Cases in the Pediatric Ward of the District Hospital of Bamako. Saudi J Med Pharm Sci 2024; 10(2): 105-109. https://doi.org/10.36348/sjmps.2024.v10i02.007.
6. Rakholia R, Rawat V, Maroof M. Liver abscess in children – Clinical profile and outcome in a resource limited setting. J Family Med Prim Care 2022; 11: 7289-93. https://doi.org/10.4103/jfmpc.jfmpc_1024_22.
7. Reyna-Sepúlveda F et al. Epidemiology and prognostic factors of liver abscess complications in northeastern Mexico. Medicina Universitaria. 2017;19(77):178-183. https://doi.org/10.1016/j.rmu.2017.10.009.
8. Asari US, Kharadi AH, Vijapura AV, Desai PD, Dabhi HR, Chaudhary TA. A retrospective observational study of liver abscess in children at tertiary care hospital of Ahmedabad city. International Journal of Health Sciences 2022:6(S3), 4921–4930. https://doi.org/10.53730/ijhs.v6nS3.6987.
9. Yeh P-J, Chen C-C, Lai M-W, Yeh H-Y and Chao H-C (2020) Pediatric Liver Abscess: Trends in the Incidence, Etiology, and Outcomes Based on 20-Years of Experience at a Tertiary Center. Front. Pediatr. 8:111. https://doi.org/10.3389/fped.2020.00111.

10. Adeniyi, O.F., Daniel, N., Ashefor, O. et al. Cryptogenic hepatic abscess in an infant and management challenges in a resource limited setting: a case report. Egypt Pediatric Association Gaz 2023;71, 40. https://doi.org/10.1186/s43054-023-00188-5.
11. Ray MS et al. Management of giant amoebic liver abscess with severe sepsis by open drainage: a study of 28 cases in 20 years. Int Surg J. 2023 Jun;10(6):1024-1030. https://dx.doi.org/10.18203/2349-2902.isj20231729.
12. Beydon M et al. Short versus long-course antibiotic therapy for pyogenic liver abscess: an emulated target trial. Clinical Microbiology and Infection 2025; 32:292—298. https://doi.org/10.1016/j.cmi.2025.10.020.
13. Giangiuli SE, Mueller SW, Jeffres MN. Transition to Oral versus Continued Intravenous Antibiotics for Patients with Pyogenic Liver Abscesses: A Retrospective Analysis. Pharmacotherapy. 2019 Jul;39(7):734-740. https://dx.doi:10.1002/phar.2296.
14. Dhabe H, Goyal A, Sanghai S. Clinical Profile of Liver Abscess In Children. Pediatr Oncall J. 2022;19: 118-121. https://doi:10.7199/ped.oncall.2022.51.
15. Mittal R, Sharma P, Varma VA, Singh D. Study of liver abscess in pediatrics patients in tertiary health care institute. IP J Surg Allied Sci. 2024;6(2):44-49. https://doi.org/10.18231/j.jsas.2024.010.